

## Treatment of Elbow Dysplasia

Diagnostic arthroscopy is considered the gold standard for treatment of CED. Arthroscopy permits minimally invasive evaluation of the joint surfaces, facilitates removal of abnormal tissue and allows for evaluation of EI. The treatment for elbow incongruency generally involves cutting the ulna below the joint.

In 2004, a total elbow replacement (TER) was introduced. TER had a reported success rate of approximately 80% in selected cases, but is considered unproved by many. TER technology is still being refined.

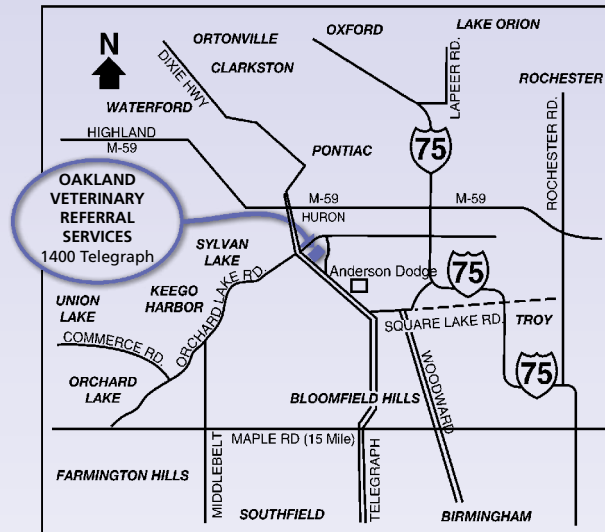
## Prognosis

Prognosis for CED depends upon how severe the arthritic changes are at the time of treatment. Typically, dogs have clinical improvement after surgery despite the persistence of arthritis. All CED patients will demonstrate progression of arthritis and may display intermittent lameness or stiffness. These patients generally respond to non-steroidal anti-inflammatory drugs (NSAIDs), chondroprotectants or agents designed to slow cartilage degradation, weight management, judicious exercise and diets containing high concentrations of omega-3 fatty acids. Future treatments for arthritis (such as TR Matrix™ injections) may prove to be beneficial for patients that do not respond to conventional treatments.

Specialty veterinary medicine is a relatively new advancement in pet care. Similar to human medicine specialists, board-certified veterinary specialists focus their education and services in one specific area.

Have you been referred?  
Things to bring at the time of your  
consultation:

- Recent radiographs and blood work
- A current list of your pet's medications



1400 Telegraph Road  
Bloomfield Hills, MI 48302  
(248) 334-6877  
Fax: 248-334-3693  
Email: [info@ovrs.com](mailto:info@ovrs.com)

[www.OVRS.com](http://www.OVRS.com)

## Oakland Veterinary Referral Services



# SURGERY

## Elbow Dysplasia

## What is Elbow Dysplasia?

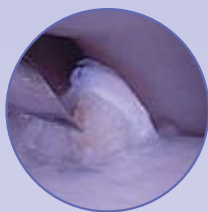The term “canine elbow dysplasia” (CED) is a general term for several conditions that result in arthritis of the elbow joint. Dogs diagnosed with elbow dysplasia suffer from one or more of the following conditions: ununited anconal process (UAP), fragmented medial coronoid process (FCP), osteochondritis dissecans (OCD) or elbow incongruency (EI). These are developmental disorders that affect primarily large and giant breed dogs. It frequently can involve both elbows. Many factors have been implicated as causes of elbow dysplasia including genetics, nutrition and trauma.

Young dogs with front limb lameness should be evaluated for CED. All forms of CED result in elbow arthritis. Early diagnosis and treatment is recommended to improve comfort, function and decrease the progression of arthritis. All dogs with FCP, OCD and UAP should be eliminated from breeding.

## Diagnosis

Clinical signs are generally first noted after 5 to 7 months of age although may not appear until the dog is older and develops signs of arthritis. The lameness is frequently most pronounced after exercise or upon rising. Affected dogs often hold the elbow close to their bodies and rotate the affected foot outwardly. Physical examination reveals elbow joint swelling, pain and reduced range of motion.

Diagnosis is confirmed by radiographs or computed tomography (CT). Radiographs can diagnose a UAP, most OCD lesions and often EI although it does not diagnose a FCP. Radiographs are also useful to rule out other conditions such as fractures or dislocations. A CT scan is necessary to visualize the FCP lesion although plain radiographs will reveal the secondary arthritis. A CT scan allows three dimensional reconstruction of the joint for more thorough evaluation of specific regions of the elbow.



*Arthroscopic view of a canine elbow joint – identification and removal of an fragmented coronoid process*

The main disadvantage of the CT scan is the need to have the dog under general anesthesia to prevent movement. When possible, surgery is performed immediately after the CT to eliminate the need for a second anesthesia.

## Types of Elbow Dysplasia

### Osteochondritis Dissecans (OCD)

Osteochondrosis is a disturbance of bone formation during growth that leads to the thickening of the joint cartilage which often progresses to separation of the cartilage (fissuring) and formation of a flap. It affects one particular area on the inside aspect of the lower humerus bone. When it becomes a flap it is known as OCD. This results in pain, swelling, inflammation and eventually arthritis. Most affected dogs are rapidly growing, large to giant breeds. Diagnosis is generally based on plain radiographs although CT can also be performed. Treatment involves removal of the cartilage flap and curettage of the defect (scraping the defect) to promote healing.

### Fragmented Medial Coronoid Process (FCP)

FCP is the most frequently encountered manifestation of elbow dysplasia. FCP commonly affects large and giant breed dogs and may be associated with abnormal loading of the coronoid if bone growth is not proportional. The coronoid forms as a separate piece of bone and produces pain, lameness, swelling and arthritis. The FCP is not visible on plain radiographs and a CT scan is advised for accurate diagnosis. Treatment consists of removal of the fragment via arthroscopy or surgery.

### Ununited Anconal Process (UAP)

UAP is found typically in large breed dogs, particularly in German Shepherd dogs. UAP is a failure of the anconal process to fuse to the ulna by 5 months of age. The loose bone fragment results in pain, swelling, lameness and arthritis. UAP can also affect both elbows. Early treatment is advised and involves surgical removal of the UAP. In some early cases, successful fusion of the fragment has occurred by performing an ulnar osteotomy (cutting the ulna).

### Elbow Incongruency (EI)

Trauma is the most common cause of growth deformities. The lower ulnar growth plate is susceptible to injury and early closure resulting in a growth disturbance between the two-bone system. Growth plate injury can produce shortening of the forelimb, external rotation, bowing and partial elbow dislocation. This results in lameness, swelling, pain and arthritis.

*Elbow dysplasia typically occurs in the bones of the humerus (OCD) and ulna (FCP and UAP).*

