

Postoperative Care & Prognosis

During the first 24 to 48 hours following surgery, icing the surgical incision (cryotherapy) combined with compression results in decreased pain, swelling and inflammation for the patient. At OVRS cryotherapy and intermittent compression treatments are performed on hospitalized patients using a Game Ready® unit. A bandage may or may not be placed for a few days postoperatively. The sutures or staples are removed 10 to 14 days after surgery.

Rehabilitation after surgery helps result in a quicker return to normal function and ensure an optimal recovery. After surgery, dogs are restricted to very short leash walks only for at least 6 to 8 weeks. Running, jumping or play sessions with other people or pets are not allowed during the recovery period.

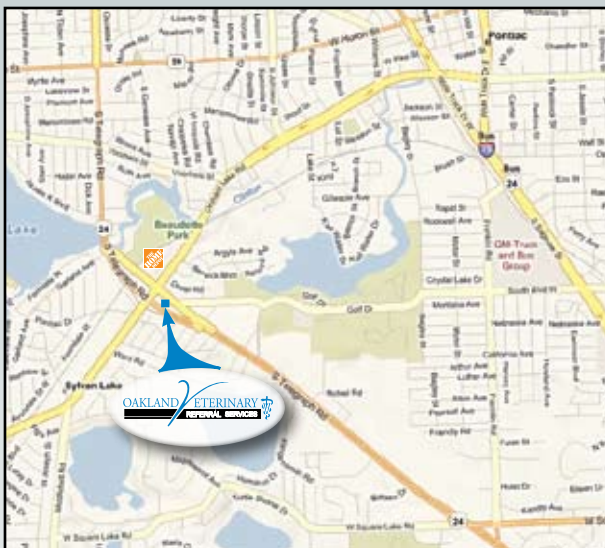
A recheck exam is performed in 6 to 8 weeks after surgery. Dogs treated with the TPLO procedure require radiographs to confirm bone healing at the 8 week recheck exam. Most dogs return to normal activity within 3 to 4 months of surgery.

Although all dogs will develop some arthritis, most dogs return to full activity. There are many treatment options available to relieve the symptoms of arthritis (nutriceuticals, anti-inflammatory medications, judicious exercise, weight control, prescription diets, acupuncture, etc.) Owners may report occasional lameness or stiffness in the leg, particularly after extended activity, after lying down for lengthy periods, or in very cold weather. Dogs treated with the TPLO have good to excellent clinical function once recovered. Complications are uncommon with these procedures.

Specialty veterinary medicine is a relatively new advancement in pet care. Similar to human medicine specialists, board-certified veterinary specialists focus their education and services in one specific area.

Have you been referred? Things to bring at the time of your consultation:

- Recent radiographs and blood work
- A current list of your pet's medications



1400 Telegraph Road
Bloomfield Hills, MI 48302
(248) 334-6877
Fax: 248-334-3693
Email: info@ovrs.com

www.OVRS.com

Oakland Veterinary Referral Services



SURGERY

Cruciate
Ligament Tears

Rupture of the cranial cruciate ligament (CCL) is one of the most common orthopedic injuries in the dog. Ruptures may be a result of trauma or a progressive degenerative condition. In cases of chronic degeneration, up to 50% of these patients may rupture the cruciate ligament in the opposite hind leg within 2 years. Rupture of the cruciate ligament results in instability of the stifle (knee joint) causing pain, lameness, and progressive arthritis.

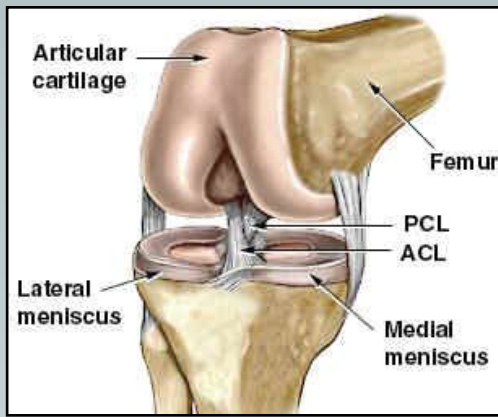
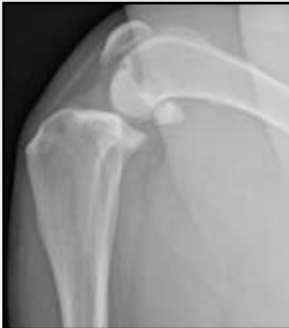Chronic instability may also result in damage to the menisci (“cushions” within the joint.) The meniscus is evaluated at surgery and if damaged, the abnormal portion will be removed. If the meniscus is normal a meniscal release may be performed.

Diagnosis

A presumptive diagnosis of a cranial cruciate ligament injury is based on the physical exam. Common findings may include pain localized to the stifle, joint effusion (swelling), medial buttress (scar tissue) formation, and detection of instability in the joint (cranial drawer sign.) The cranial drawer sign may not be obvious with CCL injuries due to incomplete tearing or chronic changes within and around the joint. Furthermore, eliciting a positive drawer sign can be difficult if the patient is overly tense or nervous. Sedation may be recommended for assessment of some patients.

Radiographs are generally advised to rule out other causes of lameness although the cruciate ligaments are not visible. Radiographs are useful to evaluate the stifle joint for swelling and arthritis secondary to the cruciate rupture, and to evaluate the tibial slope (for the TPLO procedure.) An MRI can also be used to visualize the cruciate ligaments, however it does require general anesthesia.

Lateral stifle radiograph demonstrating changes that are commonly found in patients with a cruciate ligament tear.



Treatment Options

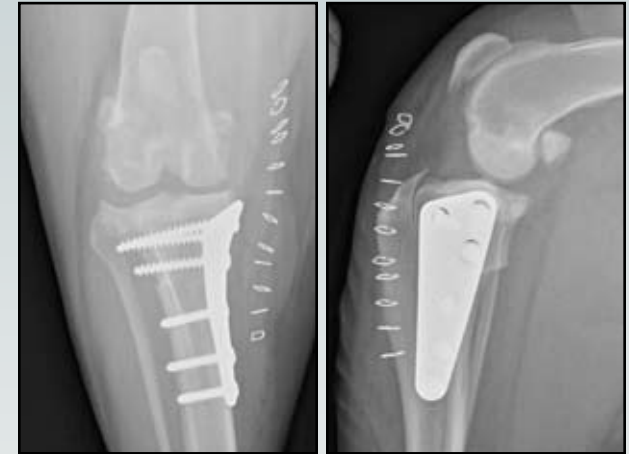Stifle instability caused by rupture of the cranial cruciate ligament will cause progressive arthritis and in most cases, a persistent lameness with an inability to return to normal activity without surgical intervention. On occasion, small breed dogs (less than 20 lbs.) and cats will return to acceptable levels of function after 4 to 8 weeks of strict rest. However, most animals eventually develop advanced arthritis without surgery. If surgery is postponed for too long, arthritis will develop, the chances of meniscal injury will increase, and the benefits from surgery will be diminished.

Extracapsular Cruciate Repair Techniques (MRIT, LFS)

Extracapsular cruciate repair techniques eliminate cranial drawer movement (joint laxity) by placement of a heavy gauge suture from around the fabella (a small bone behind the knee joint) to a hole placed in front of the tibia. This procedure ultimately relies on scar tissue formation to achieve joint stability. Postoperative restrictions are crucial to the success of this surgery. Many dogs return to ~75% function on the limb, which is usually acceptable for non-working dogs. Small dogs and cats often recover better with this surgery due to a slight difference in the biomechanics of their legs.

Tibial Plateau Leveling Osteotomy (TPLO)

The tibial plateau leveling osteotomy (TPLO) eliminates the need for the cruciate ligament by leveling the surface of the tibia (the bone below the knee joint) without disturbing the cartilage. A semicircular, full-thickness cut in the tibia is performed and the piece is rotated so that the surface is close to perpendicular to the tibia. The bone is then stabilized with a bone plate and screws. The outcome following the TPLO is characterized by early return to weight-bearing function and durable, lifelong repair. The prognosis is good to excellent, giving the best chance for resumption of normal activities for medium-to-large breed dogs (over 40 lbs.) with an active or working lifestyle, or those with other concurrent orthopedic problems.



Postoperative radiographs following a TPLO

Cruciate Ligament Tears in Cats

Cruciate ligament ruptures are rare in cats. Conservative treatment with restricted activity and weight loss (for obese cats) may result in a full return to function of the leg without surgery in an average of 4 to 8 weeks. Surgery is indicated in cats when lameness persists despite conservative treatment, or if other orthopedic conditions are present. In either case, the prognosis for cats with cruciate ligament injuries is very good.